

Brucellial Spondylodiscitis Cervical: A Case Report and Literature Review

SELLAMI A. , BOUALLAGUE M., HABCHI N.,BOUGUERRA I., BENHAFRI A.,
and DJAAFER M.

Neurosurgery Department Mustapha Pacha University Hospital – Algiers-Algeria

*Corresponding Author: : SELLAMI A.,Neurosurgery Department , Mustapha Pacha University Hospital, Algiers, Algeria

Received: December 10, 2023 **Accepted:** December 25, 2023 **Published:** January 13, 2024

Citation: SELLAMI A. , BOUALLAGUE M., HABCHI N.,BOUGUERRA I., BENHAFRI A., and DJAAFER M.
Brucellial Spondylodiscitis Cervical: About A Case. OLCIAS Journal. Vol.1(2).

Abstract :

Cervical Spondylodiscitis is a rare infectious disease. It is associated with a high risk of neurological complications. In our study, brucella was the main germ of cervical spondylodiscitis. The diagnosis of certainty is based primarily on Wright's serodiagnosis.

A 36-year-old man of rural origin was referred to the neurosurgery emergency for the management of a 04-limb deficit , Cervical MRI revealed an anterior epidural collection from C2 to C5 compressing the spinal cord, C3-C4 spondylodiscitis with vertebral compression and a left perivertebral abscess.

Urgent neurological decompression will be indicated for severe or rapidly progressive neurological disorders, with spinal cord involvement or cauda equina, due to pathological fracture or compressive epidural abscess

Wright serology was positive in our patient , a medical treatment combining double antibiotic therapy : Rifampicin and Doxycycline. The outcome was favorable, with neurological improvement and no sequelae or relapse.

Keywords: Cervical Spondylodiscitis , anterior epidural collection,decompression,serology

Introduction:

Brucellosis is an anthrozoosis still endemic in Africa and the Mediterranean basin. It can present in various forms and affect several organs(1).

Cervical localization of infectious spondylodiscitis is unusual. It is potentially serious, given the neurological complications it can cause.

The aim of our study is to determine the clinical, biological, radiological and therapeutic

features of cervical brucella spondylodiscitis (2,3).

Case Report:

A 36-year-old man of rural origin was referred to the neurosurgery emergency department of CHU MUSTAPHA for the management of a 04-limb deficit that had been progressively developing for 01 months, with no notion of trauma, fever, night sweats associated with cervical spinal pain. Clinical examination revealed a conscious patient with 2 out of 5 tetraparesis of the upper limbs and 3 out of 5 of the lower limbs, with tingling of the 04 limbs, cervical spinal pain and no notion of sphincter disorders.

Cervical MRI revealed an anterior epidural collection from C2 to C5 compressing the spinal cord, C3-C4 spondylodiscitis with vertebral compression and a left perivertebral abscess (figures 1,2,3).

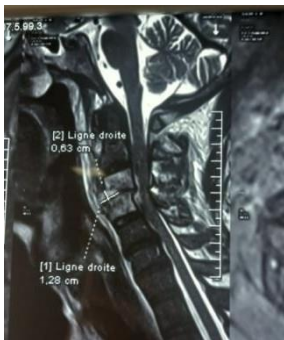


FIG :01

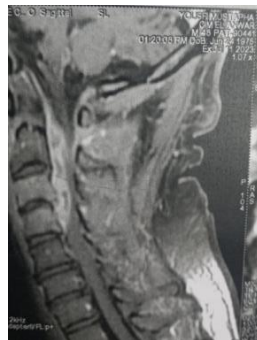

FIG :02

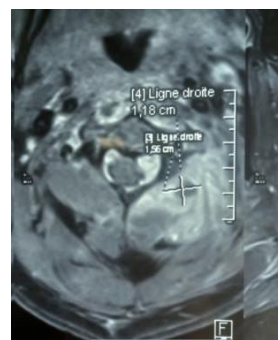


FIG :03

Fig01 , 02 , 03 : Cervical MRI revealed an anterior epidural collection from C2 to C5 compressing the spinal cord, C3-C4 spondylodiscitis

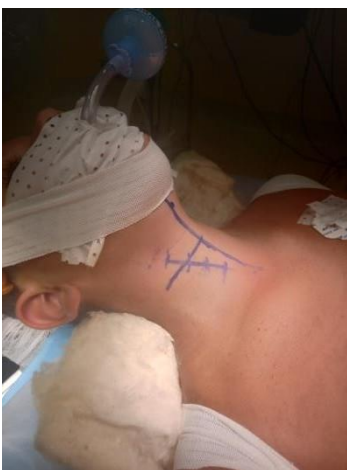

FIG :04

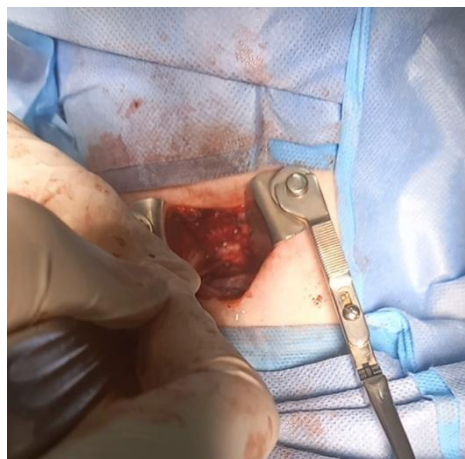

FIG :05

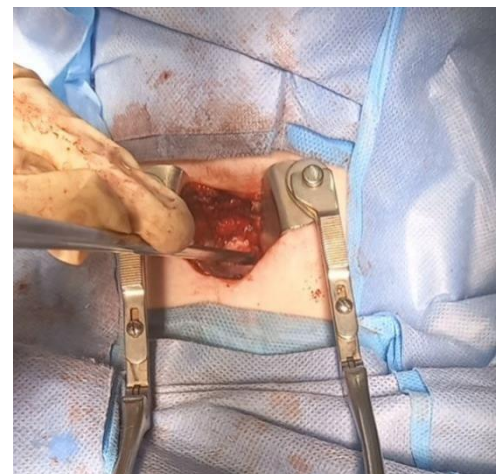

FIG :06

Fig 04 , 05 , 06 : anterolateral cervical approach

The neurosurgical indication is indicated in our patient , the patient was admitted to the operating room for an anterior decompression , by right anterolateral cervical approach , he benefited from a double Discectomy with evacuation of the anterior epidural abscessed collection under operating microscope , the posterior common longitudinal ligaments were intact (**figures 4, 5 and 6**), postoperatively, the patient was fitted with a Philadelphia cervical collar with immobilization of the cervical spine for 2 months .

Wright serology was positive in our patient (**figure7**) . A medical treatment combining double antibiotic therapy : Rifampicin and Doxycycline. The outcome was favorable, with neurological improvement and no sequelae or relapse.

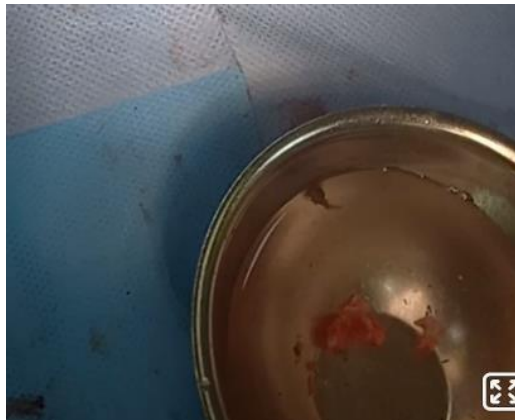

FIG :07

Fig 07: sample for cyto-bacteriological study

Discussion:

In most publications on the subject, the frequency of acute neurological disorders of any degree of severity varies between 15 and 20% (6). The vast majority of neurological deficits are therefore discrete and evolve favorably over the long term with drug treatment alone. However, unlike non-pyogenic spondylodiscitis, we must be wary of neurological deterioration in pyogenic spondylodiscitis, as it can progress dramatically and require immediate intervention (2,3).

Urgent neurological decompression will be indicated for severe or rapidly progressive neurological disorders, with spinal cord involvement or cauda equina, due to pathological fracture or compressive epidural abscess. In the case of neurological damage due to a pathological fracture, surgery will aim to decompress the spinal canal, treat the infection locally and stabilize the spine(7). An anterior approach is often required. Neurological damage due to epidural abscesses can also occur suddenly, as a result of intrarachid extension of infectious disc disease, or more rarely, hematogenous seeding from a distant site. The choice of surgical approach must take into account the location of the abscess (anterior or posterior epidural space), as well as the patient's general condition.

In well-selected cases of discrete neurological involvement without massive destruction of the vertebra and poor response to antibiotic therapy deemed adequate, percutaneous drainage of epidural abscesses appears to be a feasible option.

The use of corticosteroids has not been definitively convincing in the prevention of neurological sequelae in spinal cord trauma.6-8 In the case of infectious spondylodiscitis accompanied by spinal cord distress, we do not recommend its use either, also because of its immunosuppressive effect (7).

Conclusion:

Cervical spondylodiscitis is a rare infectious disease. It is associated with a high risk of neurological complications. In our study, brucella was the main germ of cervical spondylodiscitis. The diagnosis of certainty is based primarily on Wright's serodiagnosis.

Spondylodiscitis is a disease that has been on the increase in recent years, due to the growing number of populations at risk. Nevertheless, its discovery is often delayed due to its non-

specific symptomatology. Monitoring response to treatment is also difficult, and relies primarily on clinical findings. In many cases, a multidisciplinary approach is required.

involving infectiologists, orthopedists, neurosurgeons and radiologists. Nevertheless, proper management offers a high chance of recovery. In recent years, it has even been shown that, in cases of uncomplicated common spondylodiscitis, the duration of antibiotic therapy can be reduced to as little as 6 weeks.

References:

- 1.Zorompala A, Skopelitis E, Thanos L.** (2000). An unusual case of brucellar spondylitis involving both the cervical and lumbar spine. *J Clin Imaging* ; 24: 273-275
- 2.Turgut Tali E.**(2004). Spinal infections. *Eur J Radiol*; 50: 120-133
- 3.Pourbagher A, Pourbagher MA, Savas L, Turunc T, Demiroglu YZ, Erol I, Yalcintas D.** (2006). Epidemiologic, clinical, and imaging findings in brucellosis patients with osteoarticular involvement. *Am J Roentgenol* ;187: 873-80
- 4.Miguel PS and al.**(2006). Neurobrucellosis mimicking cerebral tumor. *Clinical Neurology And Neurosurgery* ;108:404-6
- 5.El-Desouki M.**(1991). Skeletal brucellosis: assessment with bone scintigraphy. *Radiology* ;181:415-8.
- 6.Raptopoulou and al.**(2006). Brucellar spondylodiscitis: noncontiguous multifocal involvement. *Clinical Imaging* ; 30:214- 217. doi: 10.1016/j.clinimag.2005.10.006.
- 7.Madkour MM, Sharif HS, Abed MY, Al-Fayez MA.**(1988 May). Osteoarticular brucellosis. *Am J Roentgeno*;150(5):1101–1105.